

RATIONAL IMAGING

Imaging after trauma to the neck

Bernard Wee,¹ John H Reynolds,¹ Anthony Bleetman²

¹Department of Radiology, Heart of England NHS Foundation Trust, Birmingham Heartlands Hospital, Birmingham, B9 5SS

²Department of Emergency Medicine, Heart of England NHS Foundation Trust

Correspondence to: J H Reynolds john.reynolds@heartofengland.nhs.uk

BMJ 2008;336:154-7

doi:10.1136/bmj.39433.663715.BE

Plain radiography is often used to image the neck after trauma, but computed tomography and magnetic resonance imaging provide further useful information and should be considered

The patient

A 53 year old woman presented to the emergency department after falling down a flight of stairs several hours before. She had severe neck pain but was alert and orientated; she had a score of 15 on the Glasgow coma scale. A neurological and systemic examination identified no significant findings.

What is the next investigation?

Decisions about imaging should be based on careful clinical assessment of the patient and knowledge of the mechanism of injury. Two evidence based guidelines—the Canadian cervical spine rules^{1,2} (box 1) and the NEXUS (national emergency x radiography utilization study) rules³ (box 2; fig 1)—are useful decision making tools.

Guidelines from the National Institute for Health and Clinical Excellence (NICE) in the United Kingdom recommend using an adapted version of the Canadian cervical spine rules that incorporates some aspects of the NEXUS rule to identify patients who need imaging of the cervical spine (box 3).⁴

Plain radiographs

Plain cervical radiographs are widely available and are the most common radiological examination requested when investigating suspected injury of the cervical spine. A standard series of radiographs consists of three views—anteroposterior, lateral, and anteroposterior odontoid peg views. The lateral view must show the top of the T1 vertebral body, and the odontoid peg view should show the lateral masses of the atlanto-axial articulation.

A major drawback of the plain cervical spine radiograph is that it can be difficult to obtain a technically adequate series for interpretation. The cervico-cranial and the cervico-thoracic junctions are often poorly visualised in radiographs. Consequently, although missed injuries occur at all levels, most occur at the lower cervical level and at the second cervical vertebrae (C2).⁵

Plain radiographs used in accordance with accepted guidelines are a reliable investigation for excluding

serious injury. The NEXUS group calculated that plain radiographs had a sensitivity of 99% and a negative predictive value of 99.8% when technically adequate films were obtained in accordance with their guidelines.³

Computed tomography

Computed tomography of the cervical spine is increasingly available to most emergency departments and is more sensitive than plain radiography in detecting fractures.⁶ This technique elegantly detects both soft tissue injury and bony injury—particularly if the posterior osseous elements are involved. In addition, multiplanar reformatting, which can be performed with modern multidetector scanners, allows the cervical spine to be visualised in the axial, coronal, and sagittal planes. More importantly, this technique is easier and faster to perform than plain film radiography, and is especially useful in multisystem injury, as the entire spine can be evaluated quickly and efficiently, often while scanning other regions.

Computed tomography is indicated if plain films are deemed inadequate, suspicious, or definitely abnormal, or if clinical suspicion of injury continues despite a normal radiograph.⁴ Computed tomography is superior to plain radiography, with a reported sensitivity of 100% and specificity of 99%.⁷

Computed tomography does not, however, depict soft tissue or ligamentous injuries as efficiently as magnetic resonance imaging. The radiation burden

This series provides an update on the best use of different imaging methods for common or important clinical presentations. The series advisers are Fergus Gleeson, consultant radiologist, Churchill Hospital, Oxford, and Kamini Patel, consultant radiologist, Homerton University Hospital, London.

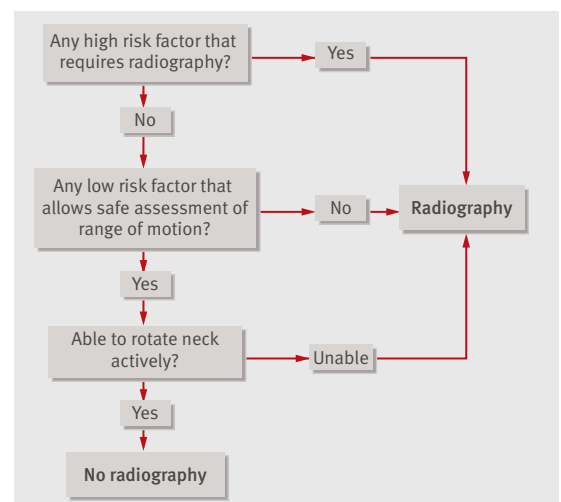


Fig 1 The Canadian cervical spine rule

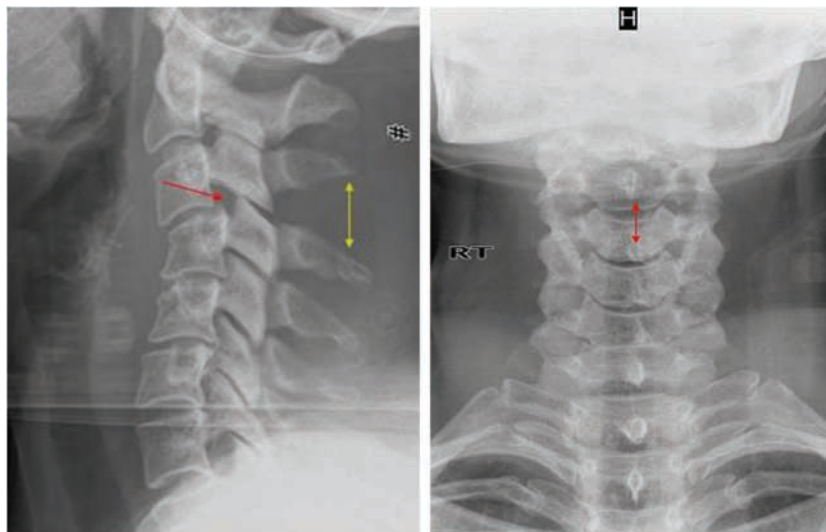


Fig 2 Initial screening lateral and anteroposterior radiographs. The lateral view (left) shows bilateral facet joint subluxation of C3 and C4 facet joints (red arrow) with splaying of the spinous processes between these vertebrae (yellow arrow). Increased interspinous distance can be seen in the anteroposterior view (right; red arrow)

of the technique can be substantial, particularly in children, and there is a small but definite risk of cancer.⁸ Radiation induced cancer is a dose dependent risk. As the thyroid gland is exposed to 14 times more radiation during computed tomography (26 mGy) than during plain radiography (1.8 mGy), this test should be used only when fully justified, with appropriate clinical stratification.⁹

Box 1 The Canadian cervical spine rule⁴

High risk factors

- Age ≥ 65 years, dangerous mechanism of injury, or paraesthesia in extremities

A dangerous mechanism of injury is considered to be a fall from a height of at least a metre or five stairs; an axial load to the head (for example, during diving); a motor vehicle collision at high speed (>100 km/h) or with rollover or ejection; a collision involving a motorised recreational vehicle; or a bicycle collision

Low risk factors

- Simple rear end motor vehicle collision, able to sit rather than lie down in the emergency department, ambulatory at any time, delayed (not immediate) onset of neck pain, or absence of midline cervical spine tenderness

A simple rear end motor vehicle collision excludes being pushed into oncoming traffic, being hit by a bus or a large truck, a rollover, and being hit by a high speed vehicle.

The Canadian cervical spine rule applies to trauma patients who are alert (Glasgow coma scale of 15) and stable. It has been shown to be safe and reliable, missing only one unstable injury in a series of 16 363 cases²

Box 2 The NEXUS guideline³

The NEXUS guideline states that radiography is indicated for patients with trauma unless all of these criteria are met:

- Absence of tenderness at the posterior midline of the cervical spine
- Absence of a focal neurological deficit
- Normal level of alertness
- No evidence of intoxication
- No painful or distracting injuries

This set of criteria has a sensitivity approaching 100% for clinically important injuries. The overall rate of missed cervical spine injuries was less than one in 4000 patients

Magnetic resonance imaging

Because this technique uses non-ionising radiation, it does not carry the radiation risk of computed tomography. The cervical spine is evaluated in three planes. The technique depicts soft tissue structures well, with reported sensitivities for intervertebral disc injury of 93%, posterior longitudinal ligament injury of 93%, and interspinous ligament injury of 100%.¹⁰ The availability of this technique for imaging of the cervical spine, however, is currently more limited than that of computed tomography, particularly out of normal working hours in smaller non-specialist centres.

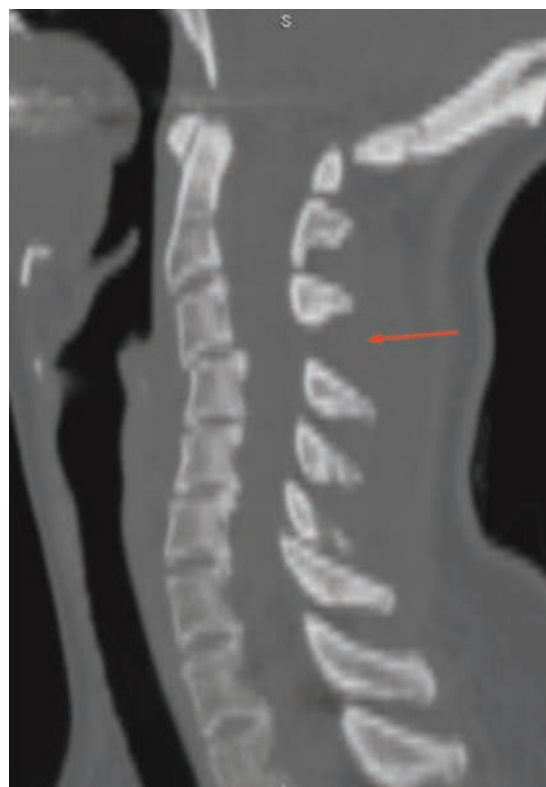

Fig 3 Sagittal computed tomography reformat on bony windows showing malalignment of the cervical spine and splaying of the spinous processes (arrow), with anterior displacement of the C3 vertebra relative to C4

Although magnetic resonance imaging is the examination of choice for evaluating soft tissue injuries, ligamentous injuries, and spinal cord injuries, computed tomography is better at detecting fractures—particularly those involving the posterior elements.¹¹ During magnetic resonance imaging, the patient is placed in a strong magnetic field, and contraindications such as pacemakers, intraorbital metal fragments, and intracranial surgical clips must be taken into account. Furthermore, traumatised patients undergoing resuscitation will be surrounded by staff and equipment that should not be exposed to the magnetic field. For practical reasons, therefore, most units need the patient to be stabilised before imaging.

The current role of magnetic resonance imaging is to determine the extent of injury to the spinal cord and soft tissue associated with bony injuries shown by plain radiography or computed tomography. It is also indicated in patients presenting with neurological signs and symptoms that might be caused by injury to the cervical spine. Pathologies that can be identified by magnetic resonance imaging include cord contusions, acute disc herniation, anterior and posterior longitudinal ligament injury, epidural haematomas, and soft tissue haematomas. Associated vertebral artery injury seen in fractures of the foramen transversarium may also be identified by this technique.¹²

Outcome of this case

The patient had sustained a neck injury by a high risk mechanism, which necessitated cervical spine radiography in accordance with NICE guidelines. We

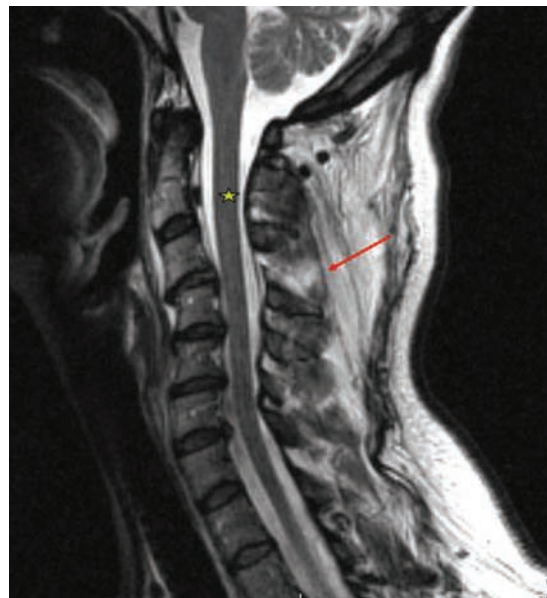


Fig 4 Sagittal T2 weighted magnetic resonance image. The affected region (arrow) shows high signal intensity associated with discontinuity of the ligamentum flavum, consistent with disruption to the ligamentum flavum and interspinous ligament. The appearance of the spinal cord (asterisk) was normal

Box 3 Summary of NICE guidelines⁴

Patients with any one of the following risk factors should have plain radiography (three views) of the cervical spine:

- Presence of neck pain or midline tenderness with:
 - Age ≥ 65 years
 - Dangerous mechanism of injury (see box 1).
- Not considered safe to assess movement in the neck for reasons other than those above
- Considered safe to assess movement in the neck, and on assessment the patient cannot actively rotate the neck 45° to the left and right. Safe assessment can be carried out if the patient:
 - Was involved in a simple rear end motor vehicle collision
 - Is comfortable in a sitting position in the emergency department
 - Has been ambulatory at any time since injury with no midline cervical spine tenderness
 - Has delayed onset of neck pain
- A definitive diagnosis of cervical spine injury is needed urgently (for example, before surgery)

obtained a standard three view series of the cervical spine (fig 2).

In view of the abnormal cervical radiograph, we performed computed tomography, which provides detailed bony visualisation and characterisation of the injury. Furthermore, the possibility of other fractures not identified on plain films had to be excluded because these would affect management. In particular, although the cervico-thoracic junction was visible on the radiograph, it was not deemed adequately visualised to exclude further injury. The scan showed an unstable cervical spine injury with bilateral anterior subluxation of the facet joints (fig 3). No other bony injury, soft tissue swelling, or haematoma was evident.

Because the patient had an unstable cervical spine injury that needed surgery, we carried out magnetic resonance imaging to map the extent of ligament injury before surgery and to exclude other associated injuries not identified on computed tomography, such as acute disc prolapse, spinal cord injury, or spinal canal haematoma. The scan showed serious injury to the interspinous ligament, but no other associated injuries (fig 4). The patient was transferred to a neurosurgical unit for spinal stabilisation with fusion of the C3 and C4 vertebrae.

The adoption of appropriate guidelines mandated that radiography be performed on this patient. Computed tomography was indicated as the plain films were abnormal, and magnetic resonance imaging—with its excellent soft tissue visualisation—showed the extent of the ligament injury and ruled out associated injuries before surgery.

LEARNING POINTS

Technically adequate radiographs of the cervical spine are essential to avoid missed injuries. Most missed spinal injuries occur in the upper and lower cervical regions, areas that are often not well visualised on poor quality films

If a patient is alert and stable, taking an appropriate history, carrying out a clinical examination, and using guidelines such as the Canadian cervical spine rules allow safe and reliable risk stratification to guide decisions about radiographic tests

Computed tomography of the cervical spine is an appropriate first line investigation in patients with suspected spinal injuries who have altered mental status, distracting injuries, or neurological deficits. It should also be considered in patients with multisystem trauma or severe head injury, which have a high incidence of cervical spine injuries

Magnetic resonance imaging provides excellent visualisation of ligament and cord injuries if the patient is stable enough to be safely scanned. It may also provide valuable information in patients with an acute neurological deficit

Contributors: All authors searched the literature and prepared, edited, and reviewed the manuscript; JHR is guarantor.

Competing interests: None declared.

Provenance and peer review: Commissioned; externally peer reviewed.

- 1 Stiell IG, Wells GA, Vandemheen KL, Clement CM, Lesiuk H, De Maio V, et al. The Canadian C-spine rule for radiography in alert and stable trauma patients. *JAMA* 2001;286:1841-8.
- 2 Stiell IG, Clement CM, McKnight RD, Brison R, Schull MJ, Rowe BH, et al. The Canadian C-spine rules versus the NEXUS low risk criteria in patients with trauma. *N Engl J Med* 2003;349:2510-8.

- 3 Hoffman JR, Mower WR, Wolfson AB, Todd KH, Zucker MI. Validity of a set of clinical criteria to rule out injury to the cervical spine in patients with blunt trauma. National Emergency X-radiography Utilization Study Group. *N Engl J Med* 2000;343:94-9.
- 4 National Institute for Health and Clinical Excellence. Clinical guideline 56. *Head injury: triage, assessment, investigation and early management of head injury in infants, children and adults*. 2007. <http://guidance.nice.org.uk/CG56>.
- 5 Davis JW, Phreaner DL, Hoyt DB, Mackersie RC. The etiology of missed cervical spine injuries. *J Trauma* 1993;34:342-6.
- 6 Griffen MM, Frykberg ER, Kerwin AJ, Schinco MA, Tepas JJ, Rowe K, et al. Radiographic clearance of blunt cervical spine injury: plain radiograph or computed tomography scan? *J Trauma* 2003;55:222-6.
- 7 Sanchez B, Waxman K, Jones T, Conner S, Chung R, Becerra S. Cervical spine clearance in blunt trauma: evaluation of a computed tomography based protocol. *J Trauma* 2005;59:179-83.
- 8 Berrington de Gonzalez, Darby S. Risk of cancer from diagnostic x-rays: estimates for the UK and 14 other countries. *Lancet* 2004;363:345-51.
- 9 Rybicki F, Nawfel RD, Judy PF, Ledbetter S, Dyson RL, Halt PS, et al. Skin and thyroid dosimetry in cervical spine screening: two methods of evaluation and a comparison between a helical CT and radiographic trauma series. *Am J Roentgenol* 2002;179:933-7.
- 10 Goradia D, Linnau KF, Cohen WA, Mirza S, Hallam DK, Blackmore CC. Correlation of MR imaging findings with intraoperative findings after cervical spine trauma. *Am J Neuroradiol* 2007;28:209-15.
- 11 Klein GR, Vaccaro AR, Albert TJ, Schweitzer M, Deely D, Karasick D, et al. Efficacy of magnetic resonance imaging in the evaluation of posterior cervical spine fractures. *Spine* 1999;24:771-4.
- 12 Katzberg RW, Benedetti PF, Drake CM, Ivanovic M, Levine RA, Beatty CS, et al. Acute cervical spine injuries: prospective MR imaging assessment at a level 1 trauma centre. *Radiology* 1999;213:203-12.

A memorable patient

John's story

I was in the saloon when the boat slammed heavily off a wave. Somewhere forward there was a noise like someone throwing a sack of potatoes into a corner. John was crumpled in an undignified position, bum through the lower bunk rails and his knees up near his chin. We hoisted him out.

The boat was travelling west, against the wind, through the huge grey waves of the Southern Ocean. Three thousand miles west of Cape Horn and 2000 miles short of New Zealand, we were constantly heeled against the prevailing westerly winds, and icy water regularly coursed the decks. The crew were tired after four weeks in this most inhospitable ocean.

Within 12 hours John had developed low abdominal pain, and his appetite began to fail; his abdomen became increasingly tender. On the second evening a fever developed, and we started intravenous antibiotics, the presumed diagnosis being an inflamed appendix. John began to vomit, and we provided him with intravenous fluids from our small supply. Despite this, he slowly dehydrated with a falling urine output. We were too far south for any merchant shipping and well out of the reach of any air rescue; the only help in thousands of square miles were the other racing yachts.

On the third day I noted atrial fibrillation, with a rate up to 140 beats/minute, a swinging fever, and an enlarging tender swelling arising out of his pelvis. We were almost out of intravenous fluids, still far out of rescue range, and in deteriorating weather. It was a real challenge to insert cannulas and keep effective intravenous fluids going while the yacht was crashing to windward. To our north west the Chatham Islands, about 700 miles off the coast of New Zealand, had just appeared on our charts.

To continue giving intravenous fluids would require more supplies. Arrangements for two yachts to return to us and transfer theirs proved difficult but was eventually

accomplished across 30 metres of rolling grey waves. The extra fluids improved John's hydration, and his arrhythmia stabilised, but the abdominal mass was now that of a 30 week pregnancy and extremely tender; he was requiring more and more pain relief.

As we slowly closed in on the Chathams, the New Zealand Maritime Rescue agency put together a complex air-sea rescue. Three aircraft and more than 100 people were eventually involved. On the sixth day, and that of the planned rescue, John began to vomit again, and as we put a dry suit on him he became hypotensive. We were concerned that he might lose consciousness in the hoist, but there was no time for him to be lifted horizontally as the helicopter was right at the limit of its fuel range.

John had emergency surgery soon after arrival in Wellington. He was septicaemic, had a huge pelvic abscess from a ruptured sigmoid diverticulum, and required a hemicolectomy and the resection of part of his small intestine. The experience is memorable not just because of John's survival but because of an exceptional piece of teamwork.

David Roche general practitioner, Wadhurst, East Sussex, and crew member in the Global Challenge Ocean Race 2004-5 drthefirm@yahoo.co.uk

We welcome articles up to 600 words on topics such as *A memorable patient*, *A paper that changed my practice*, *My most unfortunate mistake*, or any other piece conveying instruction, pathos or humour. Please submit the article on <http://submit.bmj.com>. Permission is needed from the patient or a relative if an identifiable patient is referred to. We also welcome contributions for "End-pieces," consisting of quotations of up to 80 words (but most are considerably shorter) from any source, ancient or modern, which have appealed to the reader.